



Auto-Max™

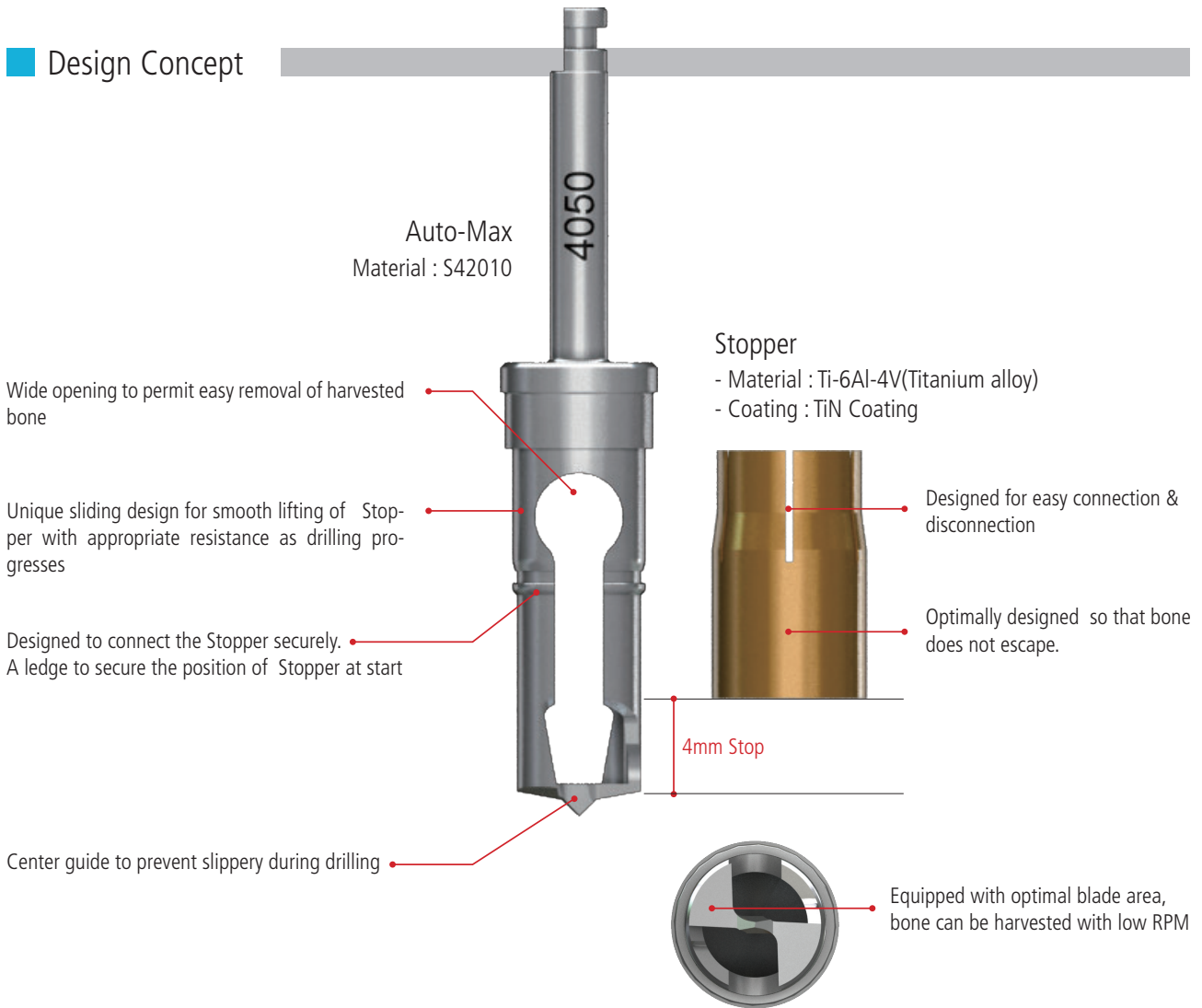


Autogeneous
Bone Harvester

Auto-Max™




■ Design Concept




Easy and Fast Insertion

- 1) Sufficient cutting force can be obtained even at low RPM.
Autogenous bone can be harvested within 10 seconds!
- 2) Amount of bone harvested may be equivalent to the size of Auto-Max!
- 3) Enables quick, easy bone harvesting in a single procedure!
- 4) It can be cleaned thoroughly as the Stopper is easily disconnectable!
- 5) V shaped opening completely prevents bone chips from splattering during drilling!
- 6) May be used in any type of bone with excellent durability!

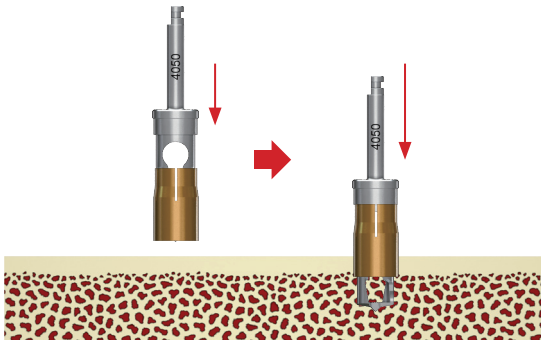


How to use

1. Connect an Auto-Max to the handpiece and position a stopper on the Auto-Max.



2. The Auto-Max should meet the bone surface perpendicularly. Press the handpiece to fix the sharp point on the bone and start drilling at about 500RPM with copious irrigation.



3. Do not pump during harvest. Pumping may scatter the harvested bone.

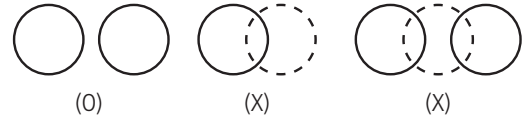
4. The Auto-Max will automatically stop advancing into the bone at a depth of 4mm.

5. Disconnect the stopper from Auto-Max and collect particulated autogenous bone in a sterilized tray.


Repeat steps 1~5 until the desired volume of bone is obtained.

6. Bone should be harvested from a new site each time avoiding overlap with other harvest sites.

[e.g.]



Products

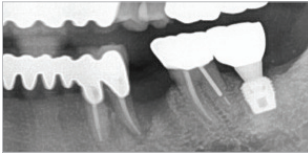


Package

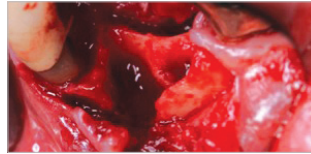
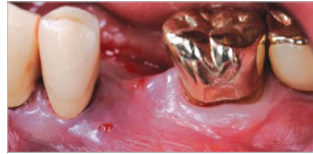


| Ref. Code | Diameter(Ø) | Ref. Code | Diameter(Ø) |
|-----------|-------------|-----------|-------------|
| AM2535 | Ø3.5 | AM5060 | Ø6.0 |
| AM4050 | Ø5.0 | AM6070 | Ø7.0 |

Clinical case 1



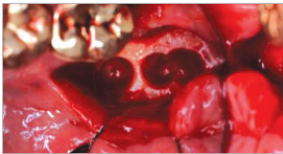Severe periodontitis on # 34. # 35 was extracted 2 months before.



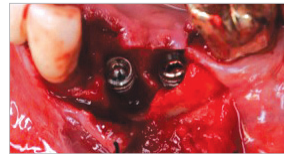

#34 was extracted and the socket was degranulated thoroughly.




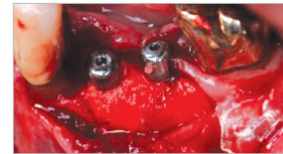
Auto-Max was prepared for bone harvesting.



Autogenous bone was harvested from the ramus.

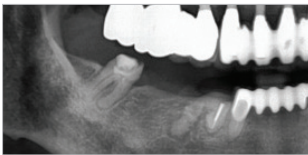


The defect was filled with shaved autogenous bone following implant placement.

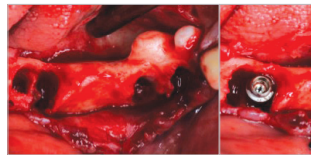
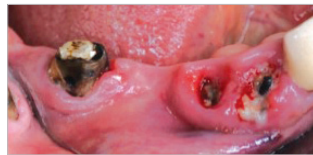

Intraoral radiograph immediate after surgery.

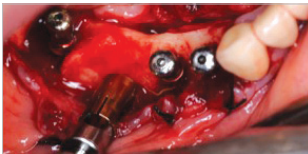
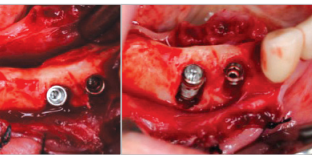
Clinical case 2



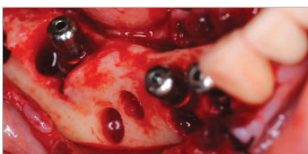The prosthetics on mandibular right molar were broken with secondary caries.



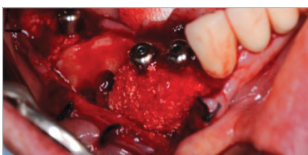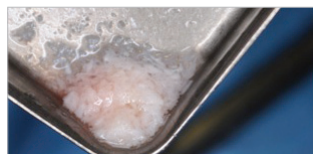Three implants were placed after extraction and degranulation of residual roots. All the implants showed bone defects.



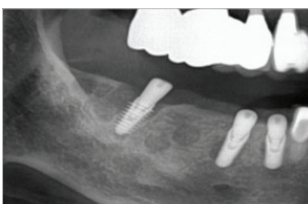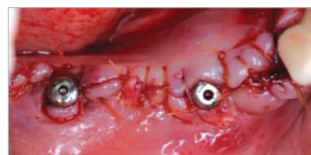
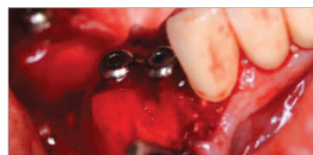
Auto-Max harvested autogenous bone from edentulous area.




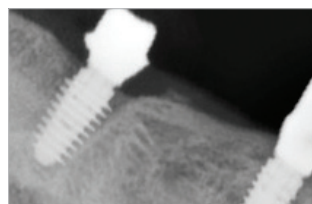
The autogenous bone was mixed with Mega-Oss bovine to increase volume of graft.



The defects were filled with the graft mixture and covered with a collagen membrane.



The panoramic radiograph taken immediately after surgery



Intraoral radiographs taken after delivery of customized abutments.